

# Radiographic Features Associated With Increased Surgical Invasiveness in Pyogenic Vertebral Column Osteomyelitis

Tangi Porea, MBChB<sup>1</sup>, Jeevan Vettivel<sup>2</sup>, Lyn Hunt, DPhil<sup>3</sup>, Peter G. Passias, MD<sup>4</sup> , and Joseph F. Baker, MCH, FRCSI<sup>1,5</sup> 

Global Spine Journal

1-8

© The Author(s) 2020

Article reuse guidelines:  
sagepub.com/journals-permissions  
DOI: 10.1177/2192568220928965  
journals.sagepub.com/home/gsj



## Abstract

**Study Design:** Single center retrospective cohort study.

**Objectives:** Assess the association between well-known radiographic features for spinal instability from the Spinal Instability in Neoplasia Score (SINS) and surgical invasiveness in treating vertebral column osteomyelitis (VCO). This will potentially help surgeons in surgical planning and aid in developing a pathology specific score.

**Methods:** Patients with VCO were identified from hospital coding. On preoperative computed tomography radiographic features, including spinal alignment, vertebral body collapse, location, type of bone lesion, and posterolateral involvement were assessed and scored 0 (stable) to 15 (highly unstable). Surgical invasiveness was graded as 0 = no surgery, 1 = decompression alone, 2 = shortening or posterior stabilization, or 3 = anterior column reconstruction.

**Results:** A total of 41 patients were included. The mean age of the cohort was 63.3 years (SD 12.0) with male comprising 78%. The mean total radiographic score for the nonsurgical group was 6.39 (3.14) and for the surgical group 10.38 (3.06),  $P < .001$ . Spinal alignment, vertebral body collapse, type of bone lesion, and posterolateral involvement correlated with surgical invasiveness (all  $P$ s  $< .05$ ). Subgroup comparison following analysis of variance showed that only spinal alignment was significantly different between groups 2 and 3.

**Conclusions:** Our findings show correlation of the radiographic components of the SINS with surgical invasiveness in management of pyogenic VCO—these findings should aid development of an “instability score” in pyogenic VCO. While most radiographic features assessed correlated with surgical invasiveness spinal alignment appears to be the key feature in determining the need for more invasive surgery.

## Keywords

pyogenic vertebral column osteomyelitis, instability, computed tomography, surgical invasiveness

## Introduction

Pyogenic spinal column infection is ever in increasing problem on a global scale.<sup>1-4</sup> Infection may present in the form of osteomyelitis, discitis, epidural abscess, or a combination with surgical intervention frequently required to prevent lasting morbidity or prevent mortality. Surgical intervention for vertebral column osteomyelitis (VCO) is indicated in cases of neurologic compromise, spinal column deformity, failed non-operative treatment, severe sepsis, intractable pain, and when there is a need to obtain microbial specimens to guide definitive antimicrobial treatment.<sup>5-7</sup> In selected cases, the VCO itself does not need surgical intervention but an associated

epidural abscess or paravertebral abscess needs addressing. For reconstructive procedures, there are a range of considerations

<sup>1</sup> Waikato Hospital, Hamilton, New Zealand

<sup>2</sup> Monash University, Clayton, Victoria, Australia

<sup>3</sup> Department of Computing and Mathematical Sciences, University of Waikato, Hamilton, New Zealand

<sup>4</sup> NYU Langone Medical Centre, New York, NY, USA

<sup>5</sup> University of Auckland, Auckland, New Zealand

### Corresponding Author:

Joseph F. Baker, Department of Orthopaedic Surgery, Waikato Hospital, Pembroke Street, Hamilton, New Zealand.  
Email: joe.baker@auckland.ac.nz



for the surgeon, including approach to the spine, implant material, and reconstructive techniques.<sup>8-12</sup> Advanced imaging in the form of magnetic resonance imaging (MRI) and computed tomography (CT) is frequently obtained for the diagnosis and surgical planning; however, the utility of disease progression evident on these modalities has not been evaluated as a potential guide for surgical reconstruction.<sup>13,14</sup>

The Spinal Instability in Neoplasia Score (SINS) was reported in 2010 as a guide to evaluating stability, or lack of, in metastatic spine disease.<sup>15</sup> SINS assesses 5 separate radiographic features—location of the lesion, type of lesion (ie, lytic, blastic, or mixed), spinal alignment, vertebral body collapse, and involvement of the posterolateral structures—and, in addition to a pain score, provides the clinician with a scale to guide the need for prophylactic stabilization of destructive spine pathology. The SINS is easy to use with acceptable reliability among experienced clinicians as well as those at residency level.<sup>16-18</sup> A similarly constructed score for pyogenic spinal column infection is thus appealing to guide the treating clinician however currently lacking and the application of the radiographic criteria of the SINS to a pyogenic VCO cohort not before reported.

Although pyogenic infection represents a distinctly different pathophysiology to metastatic disease, it nonetheless also has the potential to result in destructive spinal lesions and neurologic compromise.<sup>19,20</sup> Bony destruction, no matter what the underlying etiology may result in vertebral body collapse, instability, or malalignment. Disease may spread through the vertebral body to involve the posterior elements. The appearance of the lesion may differ between metastatic disease and pyogenic infection; however, at various time points in the pathologic process both may result in a lytic appearance with frank bony destruction—particularly adjacent to the disc space—and both may have a more sclerotic appearance, either as a result of primary tumor behavior or a reparative response to perhaps a pathologic fracture.<sup>13,21</sup>

The aim of this study was therefore to determine the association of surgical intervention in a cohort of patients with primary vertebral column osteomyelitis with the radiographic components of the SINS. Findings from this analysis will potentially allow surgeons to improve surgical planning, enhance patient counseling, and potentially contribute to a pathology-specific score.

## Materials and Methods

Institutional approval from the hospital Clinical Audit Support Unit (Ref: 3472) was obtained for an outcomes' analysis of cases of spinal column infection from 2007 to 2017.

Patients aged >18 years with VCO were identified from hospital coding. These were cross-referenced against the imaging database and clinical records generating a cohort of pyogenic VCO—all had preoperative plain radiographs, MRI, and CT imaging available which reflects our current standard assessment for all patients undergoing surgical intervention for VCO. While all patients treated had all imaging modalities

**Table 1.** Radiographic Features According to the Spinal Instability in Neoplasia Score (SINS) and Allocated Scoring.

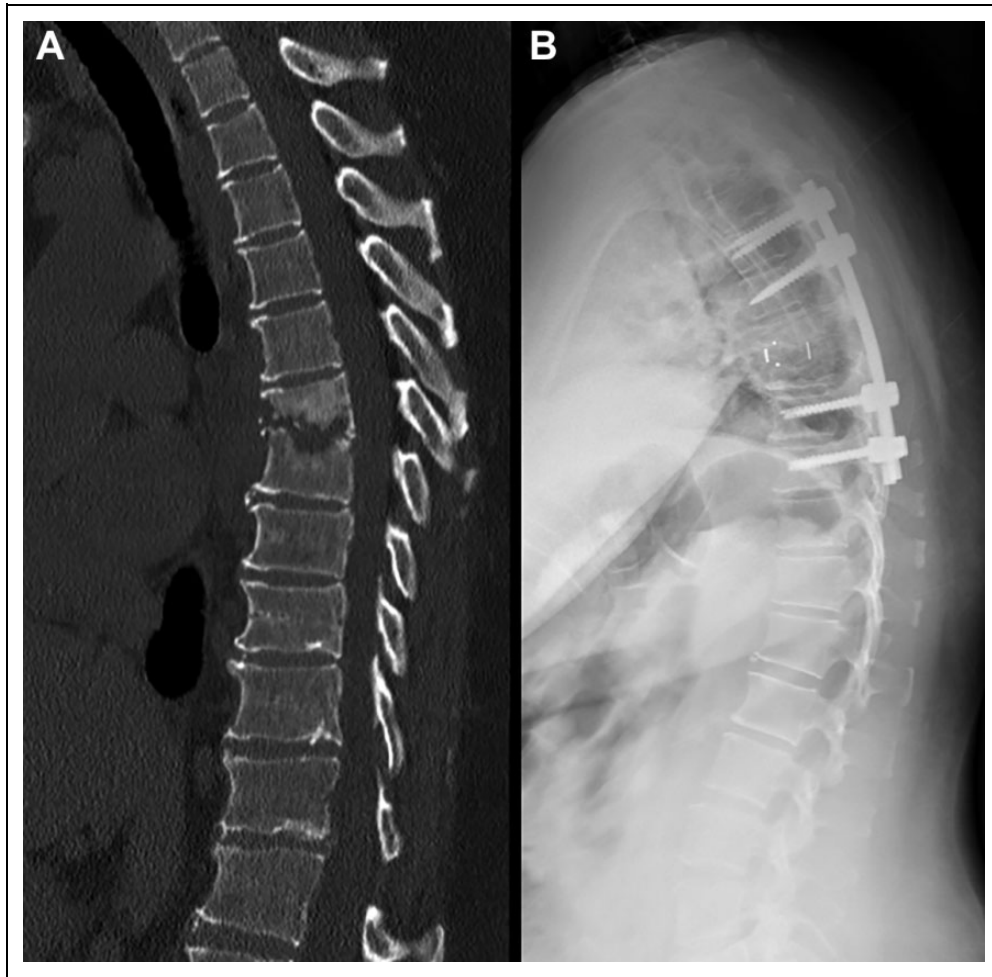
Radiographic component	Score
<b>Location</b>	
Junctional	3
Mobile spine	2
Semirigid	1
Rigid	0
<b>Bone lesion</b>	
Lytic	2
Mixed	1
Blastic	0
<b>Spinal alignment</b>	
Subluxed/translated	4
Kyphosis/scoliosis	2
Normal	0
<b>Vertebral body collapse</b>	
>50% collapse	3
<50% collapse	2
No collapse but >50% body involved	1
None	0
<b>Posterolateral involvement</b>	
Bilateral	3
Unilateral	1
None	0
<b>Total</b>	<b>0-15</b>

available, this study utilized CT for assessing the radiographic changes as in our experience this modality provides a clearer picture of osseous disease. All patients included in this study either had positive microbiologic results from intraoperative culture or positive blood culture results in the setting of established radiographic disease.

Basic demographic details including age and gender were collected. Clinical characteristics of the VCO were recorded including microbiologic results. Surgical details were noted including approach used and reconstructive techniques deployed.

SINS was developed as a tool to guide prophylactic stabilization of the spinal column afflicted by metastatic disease.<sup>15</sup> A score is developed from combination of radiographic features and the degree of pain experienced by an individual but in this current study only the radiographic criteria are assessed thus enabling a total score from 0 to 15. Radiographic criteria and associated scoring from the SINS and applied to this current cohort are shown in Table 1. All radiographic scores were made using computed tomography taken prior to surgery. All scoring was performed while blinded to the subsequent surgical intervention. Inter- and intraobserver errors were similarly performed, in blinded fashion, 6 weeks apart.

This was a single-center study performed at tertiary referral center for spine surgery, serving a catchment of over 900 000. Three fellowship-trained spine surgeons were involved in the surgical management of these patients. In this center, patients with pyogenic spinal column disease are managed with input from both the Spinal Service and Infectious Disease Service.



**Figure 1.** Preoperative computed tomography (A) and postoperative radiograph (B) in a patient with T6/7 discitis and associated vertebral column osteomyelitis. The patient underwent debridement, PEEK (polyetheretherketone) cage insertion and posterior stabilization (invasiveness: 2).

Surgical intervention was considered along a spectrum of invasiveness reflecting a more aggressive form of reconstruction. This ranged from: no surgery (0); decompression alone (1); disc space debridement or spinal column shortening with posterior stabilization (2), to; anterior column reconstruction using expandable cages/allograft or autograft blocks via either an anterior or posterior approach (3) (Figures 1 and 2). Decompression alone (procedure code 1) was indicated for sepsis, pain, or neurologic deficit. In the more invasive surgical groups (procedure codes 2 and 3), in addition to the aforementioned, potential instability and bone loss was judged by the individual surgeon at the time, and the most appropriate reconstructive technique employed.

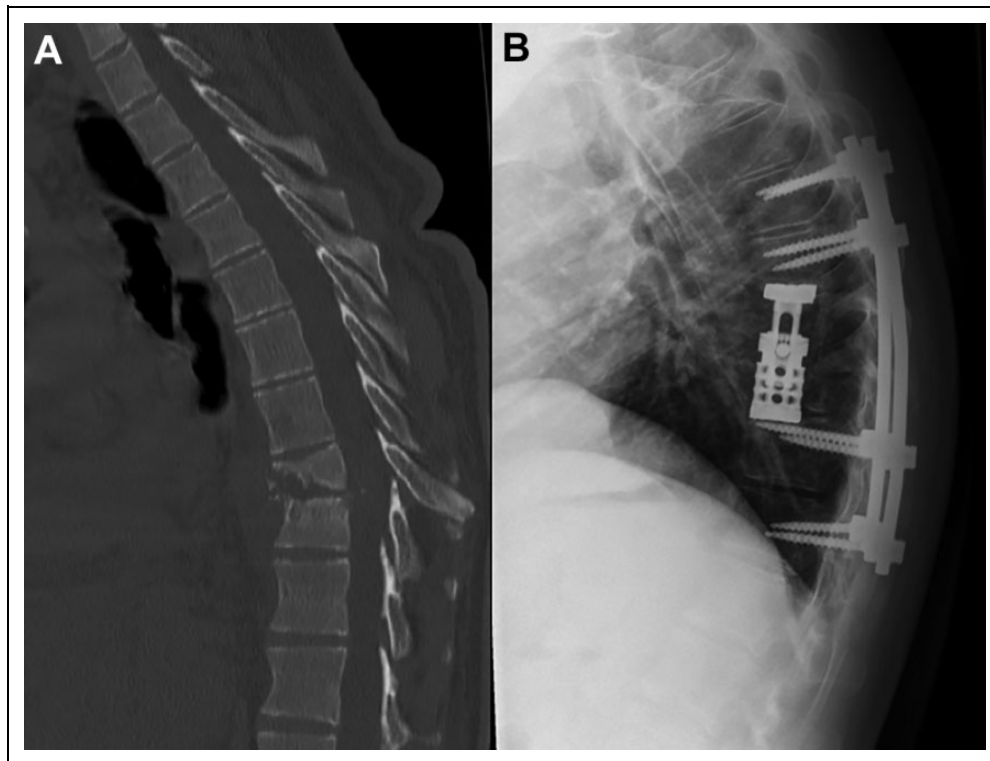
### Statistical Analysis

Results are reported as mean (standard deviation). Inter- and intraobserver reliability was performed using intraclass correlation coefficients and standardized Cronbach's  $\alpha$ —this was performed by 2 surgeons, on 10 randomly selected cases, in a blinded fashion with a 6-week “washout” period between

assessments. Group comparisons were performed using Mann-Whitney 2-tailed tests. Proportions were tested using a 2-sample Z-test. Spearman correlation was used to determine associations. One-way analysis of variance (ANOVA; Kruskal-Wallis) for nonparametric data was used to identify differences in the radiographic scores according to surgical invasiveness—there was no cell size imbalance of more than 1:4 permitting the use of ANOVA.<sup>22</sup> To assess for differences between the four levels of surgical invasiveness pairwise comparisons were performed using Dunn's procedure allowing for Bonferroni correction. Multivariate analysis was performed using a stepwise analysis of covariance (ANCOVA) to determine the influence of significant variables on surgical invasiveness where appropriate. Statistical significance was set at  $P < .05$  throughout.

### Results

A total of 41 patients were included. The mean age of the cohort was 63.3 years (SD 12.0) with male comprising 78%. The most common organism found was *Staphylococcus aureus*, accounting for 41% of cases. Twenty (49%) required no surgical



**Figure 2.** Preoperative computed tomography (CT) (A) and postoperative radiograph (B) in a patient with T8/9 vertebral column osteomyelitis. The patient underwent anterior column reconstruction using an expandable cage via thoracotomy and posterior stabilization (invasiveness: 3).

intervention and 21 (51%) underwent surgery, of which, by location, included 21% cervical, 21% thoracic, and 58% lumbar. In the surgical group, 6 patients underwent decompression alone, 8 shortening and/or posterior stabilization alone, and 7 anterior column reconstruction with or without posterior stabilization. Full details of the cohorts are shown in Table 2. In the surgical group, a greater proportion of patients had a spinal epidural abscess (43% vs 15%;  $P = .085$ ), discitis (86% vs 50%;  $P = .021$ ), and number of spinal levels involved (2.5 vs 1.8;  $P = .029$ ). The nonsurgical cohort was more frail according to the modified Frailty Index–11 (mFI-11; 1.9 vs 1.0;  $P = .01$ ). The mean hemoglobin (112.1 vs 117.1 g/L), white cell count (12.6 vs 12.69), C-reactive protein (134.2 vs 127.8 mg/L), and serum albumin (31.4 vs 27.15 g/L) were similar for each group. Mortality at 1 year was 25% and 14% in the nonoperative and operative groups, respectively ( $P = .62$ ).

The mean (SD) radiographic score for each the nonsurgical and surgical group was 6.39 (3.14) and 10.38 (3.06),  $P < .001$ , respectively. Table 3 shows the mean values for each of the radiographic criteria for the nonoperative and operative groups and Table 4 results from reliability analysis.

Table 5 shows results from correlation analysis between each radiographic feature assessed and surgical invasiveness. Pairwise comparison, using a corrected significance level of .0083, demonstrated significant differences in: the type of lesion between groups 0 and 3 ( $P = .04$ ); change in alignment between groups 0 and 3 ( $P < .001$ ) and groups 2 and 3 ( $P = .010$ ); vertebral body collapse between groups 0 and 2 ( $P = .006$ ) and groups 0

and 3 ( $P = .009$ ); and posterolateral involvement between groups 0 and 2 ( $P = .006$ ) and groups 0 and 3 ( $P = .001$ ). Overall, the total score was significantly different between groups 0 and 2 ( $P = .018$ ) and groups 0 and 3 ( $W = 4.74$ ;  $P < .001$ ). Complete results from ANOVA are shown in Table 6.

Multivariate analysis was performed incorporating the number of levels involved, mFI-11 score, presence of discitis, and total radiographic score. Only the total radiographic score remained a significant predictor of the level of surgical intervention with the following equation:

$$\text{Procedure code} = -0.57 + 0.20 \times \text{Total}$$

## Discussion

Although numerous studies highlight the successful outcome following varied reconstructive strategies, there has been little if any attention given to the potential for a formal radiographic assessment of spinal stability in the setting of pyogenic VCO.<sup>12,23-25</sup> The primary aim of this study was to examine the radiographic changes evident in pyogenic VCO and relate these to surgical intervention. The results demonstrated a positive association with moderate correlation between the invasiveness of surgical intervention and severity of radiographic features.

Significant differences between the radiographic score according to level of surgical invasiveness were demonstrated in the degree of vertebral body collapse, spinal alignment, and involvement of posterolateral elements—all anticipated

**Table 2.** Details of the Study Cohort.<sup>a</sup>

Patient	Age, y	Gender	Organism	SEA	Discitis	Levels	Neurology	mFl-II	Procedure code	Location	Bone lesion	Alignment	Collapse	PL involvement	Total
1	66	M	<i>Staphylococcus aureus</i>	0	1	2	1	3	0	2	0	0	0	0	2
2	79	M	<i>Escherichia coli</i>	0	1	1	0	2	0	3	2	0	2	0	7
3	76	M	<i>S aureus</i>	0	0	2	0	0	0	1	2	1	3	0	7
4	83	M	<i>Klebsiella pneumoniae</i>	1	1	2	0	2	0	3	2	2	2	0	9
5	41	F	MRSA	1	1	3	0	2	0	2	2	2	0	0	6
6	79	M	<i>Enterococcus faecalis</i>	0	0	2	0	3	0	3	2	2	2	3	12
7	70	F	<i>K pneumoniae</i>	1	0	2	0	2	0	3	2	2	3	0	10
8	51	M	MRSA	0	0	1	1	0	0	3	2	0	0	0	5
9	51	M	<i>S aureus</i>	0	1	2	0	2	0	2	1	2	0	0	5
10	84	M	<i>Staphylococcus lugdunensis</i>	0	0	2	0	5	0	2	1	2	0	0	5
11	55	M	Coagulase negative <i>S aureus</i>	0	1	2	0	3	0	2	2	2	3	1	10
12	40	M	<i>S aureus</i>	0	0	1	0	0	0	1	1	0	0	0	2
13	58	F	Coagulase negative <i>S aureus</i>	0	0	3	0	3	0	0	0	0	0	0	0
14	77	M	Coagulase negative <i>S aureus</i>	0	1	1	0	4	0	3	1	2	2	0	8
15	74	M	<i>E coli</i>	0	0	3	0	3	0	2	1	0	0	0	3
16	63	M	Coagulase negative <i>S aureus</i>	0	1	2	1	1	0	3	2	0	2	0	7
17	47	M	MRSA	0	0	1	1	2	0	1	1	0	0	0	2
18	69	M	<i>E coli</i>	0	1	2	0	0	0	2	1	4	2	0	9
19	50	M	Coagulase negative <i>S aureus</i>	0	1	2	1	0	0	2	2	2	0	0	6
20	72	M	<i>S aureus</i>	0	0	1	1	1	0	3	2	4	3	1	13
21	71	F	<i>S aureus</i>	1	1	2	1	1	1	2	2	2	2	3	11
22	54	F	MRSA	1	1	2	0	0	1	3	1	2	2	0	8
23	57	M	<i>S aureus</i>	1	1	2	1	1	1	1	2	2	2	0	7
24	65	M	<i>E coli</i>	1	0	4	1	2	1	2	2	2	0	0	6
25	50	M	<i>S aureus</i>	0	1	2	0	2	1	3	2	4	3	3	15
26	69	M	<i>S aureus</i>	1	1	2	0	1	1	3	1	2	2	0	8
27	60	M	<i>S aureus</i>	0	1	5	1	0	1	3	1	2	3	0	7
28	56	M	<i>S aureus</i>	1	1	2	1	1	2	1	2	2	3	3	11
29	68	M	<i>S aureus</i>	1	1	2	0	2	2	3	2	1	2	1	9
30	68	M	<i>S aureus</i>	1	1	2	0	2	2	3	2	0	1	1	7
31	56	F	<i>S aureus</i>	0	1	1	1	0	2	3	1	2	2	0	8
32	51	M	<i>S aureus</i>	0	1	2	0	0	2	1	2	2	3	3	11
33	76	M	<i>Enterococcus sp</i> ; <i>Clostridium sp</i>	0	1	2	0	0	2	3	1	2	3	1	10
34	83	M	<i>S aureus</i>	0	1	6	0	0	2	3	2	2	3	3	13
35	44	M	<i>S aureus</i>	0	1	1	0	2	3	3	2	2	0	0	7
36	57	F	Coagulase negative <i>S aureus</i>	0	1	4	0	2	3	3	2	2	3	3	13
37	60	M	<i>Mycobacterium avium</i>	1	1	2	1	1	3	3	2	4	3	3	15
38	80	F	<i>E coli</i> ; <i>E faecalis</i>	0	0	3	0	2	3	3	2	4	3	3	15
39	64	M	<i>Serratia marcescens</i>	0	0	2	0	1	3	2	2	4	3	1	12
40	58	F	<i>S aureus</i> ; <i>E coli</i>	0	1	2	1	0	3	3	2	4	3	3	15
41	64	M	<i>Staphylococcus epidermidis</i>	0	1	2	1	0	3	2	1	4	2	1	10

Abbreviations: M, male; F, female; SEA, spinal epidural access; mFl-II, modified Frailty Index-II; PL, posterolateral; MRSA, methicillin-resistant *Staphylococcus aureus*.

<sup>a</sup>SEA (0 = absent; 1 = present); discitis (0 = absent; 1 = present); neurologic deficit (0 = absent; 1 = present).

**Table 3.** Comparison of the Radiographic Scores for the Nonsurgical and Surgical Groups (2-Tailed Mann-Whitney).<sup>a</sup>

	Location	Lesion	Alignment	Collapse	Posterolateral involvement	Total score
No surgery	2.25 (0.80)	1.36 (0.62)	1.36 (1.19)	1.11 (1.26)	0.32 (0.82)	6.39 (3.14)
Surgery	2.43 (0.81)	1.71 (0.46)	2.42 (1.12)	2.29 (0.96)	1.52 (1.36)	10.38 (3.06)
P	.014	.037	.003	.001	<.001	<.001

<sup>a</sup>Scores are given as mean (SD).

**Table 4.** Inter- and Intraclass Coefficients for Reliability Analysis of Each Component of and the Total Radiographic Score.

	Interrater	Intrater
Location	0.950	0.950
Lesion	0.300	0.333
Alignment	0.840	0.895
Collapse	0.806	0.808
Posterolateral	0.641	0.646
Total	0.865	0.908

radiographic changes with progression of vertebral column osteomyelitis. Based on this small cohort analysis, the most clinically relevant radiographic feature that may be able to guide clinicians was the severity of malalignment—this was the only radiographic feature that was significantly different in between the surgical cohorts 2 (disc space debridement/vertebral column shortening) and 3 (anterior column reconstruction). Anticipating the need for anterior column debridement and reconstruction allows appropriate patient counseling and adequate preparation. However, vertebral body collapse, reflective of destructive lysis, almost certainly contributes to the malalignment and incompetence of the posterolateral structures may develop as a result of kyphosis and facet joint distraction—indeed one could anticipate increase risk of instability with gapping of the facets as has been well described in spinal tuberculosis.<sup>26</sup> A larger cohort with increased subgroup numbers would help establish the contribution of these radiographic features.

It is also worth noting that 2 patients with high SINS were eventually managed nonoperatively due to unacceptable risk of perioperative mortality—exclusion of these patients may have resulted in a stronger correlation of the radiographic score with surgical invasiveness but at the same time lost a degree of generalizability. It must be remembered that any scoring system is a guide and ultimately surgical decision making incorporates a host of factors.

The importance of spinal alignment in SINS, or loss thereof, has been highlighted previously. In a cohort of 311 patients with metastatic spine disease, Park et al<sup>27</sup> found that the spinal alignment and vertebral collapse were significantly associated with the need for anterior column support. Although loss of normal spinal alignment appears to suggest the need for anterior column support, the treating surgeon must then consider the ideal approach and also implant material—both controversies that are beyond the scope of this initial investigation.<sup>28</sup>

The location of the VCO did not correlate with surgical invasiveness. This is somewhat surprising given our understanding of spinal biomechanics. It is likely this variable it failed to correlate significantly due to a relatively small sample size—with a larger sample more junctional disease may have influenced the statistical analysis more strongly.

The SINS was designed for use in metastatic spine disease. Pyogenic infection and metastatic disease share similarities in the destructive pathology encountered in the spinal column and left unchecked both can result in spinal instability and a threat to the neurologic structures. SINS has been shown to be a robust, reliable, and reproducible instrument for assessing spinal instability. Multiple studies have shown more than acceptable inter- and intraobserver agreement for the radiographic features described.<sup>16-18,29</sup> This study is the first, to our knowledge, to report on the relationship between defined radiographic changes and invasiveness of surgical intervention in pyogenic VCO and provides the first step for development of a structured “instability score” specific for pyogenic VCO.

We acknowledge that this study has weaknesses, including it being a retrospective study, which relies on quality of data input and documentation from which the results are derived from. The overall cohort was relatively small but came from a single tertiary referral center. A larger cohort study, perhaps derived from multiple centers to reflect the potential for regional variation in patient and surgeon characteristics, would overcome this weakness and appears a next logical step in developing a pathology-specific score. This would also allow possible validation of any scoring system which is a constant challenge for clinicians—being sure that new treatment algorithms are appropriate for local use is a key step before full implementation.

Although small, the study cohort was of similar composition to other reports on pyogenic spinal column infection. We found a male predominance and a mean age of 63.3 years—Kim et al<sup>30</sup> reported on a cohort of 441 patients with native vertebral osteomyelitis—63% were male and the mean age was 64 years. In a systematic review of 50 studies assessing treatment of spondylodiscitis, Taylor et al<sup>31</sup> reported a male majority (60%) and a mean age of 58.3 years.

Imaging modality must also be considered—we have relied solely on supine CT for radiographic analysis—this may have resulted in an underestimation of the degree of vertebral body collapse or deformity; erect radiographs would provide a more accurate reflection of these characteristics. However, in select patients erect imaging may not be tolerated or may even be

**Table 5.** Spearman *r* Values From the Correlation Analysis Between Surgical Invasiveness Score and Radiographic Characteristics Assessed.<sup>a</sup>

	Location	Bone lesion	Spinal alignment	Vertebral body collapse	Posterolateral involvement	Total score
Surgical invasiveness	0.158 [−0.129, 0.420] <i>P</i> = .279	0.314 [0.036, 0.547] <i>P</i> = .028	0.485 [0.235, 0.674] <i>P</i> < .001	0.466 [0.213, 0.661] <i>P</i> < .001	0.531 [0.294, 0.707] <i>P</i> < .001	0.592 [0.373, 0.749] <i>P</i> < .001

<sup>a</sup>Values are presented as *r* [95% confidence interval] *P* value.

**Table 6.** Complete Results From ANOVA With Pairwise Comparisons Using a Bonferroni Correction (Corrected Significance Level of .0083.<sup>a</sup>

	Surgical invasiveness				
	0	1	2	3	
Location	0	1	.820	.774	.165
	1	.820	1	.981	.384
	2	.774	.981	1	.362
	3	.165	.384	.362	1
Lesion	0	1	.256	.281	<b>.040</b>
	1	.256	1	.885	.520
	2	.281	.885	1	.399
	3	<b>.040</b>	.520	.399	1
Alignment	0	1	.068	.555	<b>&lt;.001</b>
	1	.068	1	.280	.182
	2	.555	.280	1	<b>.010</b>
	3	<b>&lt;.001</b>	.182	<b>.010</b>	1
Collapse	0	1	.317	<b>.006</b>	<b>.009</b>
	1	.317	1	.221	.237
	2	<b>.006</b>	.221	1	.995
	3	<b>.009</b>	.237	.995	1
Posterolateral involvement	0	1	.331	<b>.006</b>	<b>.001</b>
	1	.331	1	.215	.077
	2	<b>.006</b>	.215	1	.544
	3	<b>.001</b>	.077	.544	1
Total	0	1	.099	<b>.018</b>	<b>&lt;.001</b>
	1	.099	1	.706	.146
	2	<b>.018</b>	.706	1	.242
	3	<b>&lt;.001</b>	.146	.242	1

<sup>a</sup>Statistically significant *p*-values appear in bold-type.

contraindicated, for example, if there was existing neurologic compromise. CT is acknowledged as a sensitive modality for assessing bone loss and for surgical planning although it lacks the sensitivity of MRI for diagnosis early in the disease process.<sup>14</sup>

Additional detail on patient outcome would be helpful to gauge the utility of any scoring system however this is beyond the intention of this initial exploration—further work arriving at an ideal score would ideally determine whether or not application of such as score resulted in improvements in quality of life and functional outcome.

In summary, this study analysed the radiographic features associated with level of surgical invasiveness in a cohort of patients with pyogenic VCO. We determined that spinal alignment, posterolateral involvement, and vertebral body collapse were associated with increased invasiveness. The strongest trend was noted between spinal alignment and surgical

invasiveness. A disease specific “instability score” is an attractive concept to guide the treating clinician in managing pyogenic VCO and our findings form the basis for its development. A multicentre approach appears a logical next step.

**Declaration of Conflicting Interests**

The author(s) declared no potential conflicts of interest with respect to the research, authorship, and/or publication of this article.

**Funding**

The author(s) received no financial support for the research, authorship, and/or publication of this article.

**ORCID iD**

Peter G. Passias, MD  <https://orcid.org/0000-0003-2635-2226>  
Joseph F. Baker, MCH, FRCSI  <https://orcid.org/0000-0002-8518-8780>

**References**

1. Akiyama T, Chikuda H, Yasunaga H, Horiguchi H, Fushimi K, Saita K. Incidence and risk factors for mortality of vertebral osteomyelitis: a retrospective analysis using the Japanese diagnosis procedure combination database. *BMJ Open*. 2013;3:e002412.
2. Chong BSW, Brereton CJ, Gordon A, Davis JS. Epidemiology, microbiological diagnosis, and clinical outcomes in pyogenic vertebral osteomyelitis: a 10-year retrospective cohort study. *Open Forum Infect Dis*. 2018;5:ofy037.
3. Issa K, Diebo BG, Faloon M, et al. The epidemiology of vertebral osteomyelitis in the United States from 1998 to 2013. *Clin Spine Surg*. 2018;31:E102-E108.
4. Vettivel J, Bortz C, Passias PG, Baker JF. Pyogenic vertebral column osteomyelitis in adults: analysis of risk factors for 30-day and 1-year mortality in a single center cohort study. *Asian Spine J*. 2019;13:608-614.
5. Boody BS, Jenkins TJ, Maslak J, Hsu WK, Patel AA. Vertebral osteomyelitis and spinal epidural abscess: an evidence-based review. *J Spinal Disord Tech*. 2015;28:E316-E327.
6. Acosta FL Jr, Chin CT, Quinones-Hinojosa A, Ames CP, Weinstein PR, Chou D. Diagnosis and management of adult pyogenic osteomyelitis of the cervical spine. *Neurosurg Focus*. 2004;17:E2.
7. Barnes B, Alexander JT, Branch CL Jr. Cervical osteomyelitis: a brief review. *Neurosurg Focus*. 2004;17:E11.
8. Aryan HE, Lu DC, Acosta FL Jr, Ames CP. Corpectomy followed by the placement of instrumentation with titanium cages and recombinant human bone morphogenetic protein-2 for vertebral osteomyelitis. *J Neurosurg Spine*. 2007;6:23-30.

9. Chen WH, Jiang LS, Dai LY. Surgical treatment of pyogenic vertebral osteomyelitis with spinal instrumentation. *Eur Spine J.* 2007;16:1307-1316.
10. Gorenssek M, Kosak R, Travnik L, Vengust R. Posterior instrumentation, anterior column reconstruction with single posterior approach for treatment of pyogenic osteomyelitis of thoracic and lumbar spine. *Eur Spine J.* 2013;22:633-641.
11. Menon VK, Kumar KM, Al Ghafri K. One-stage biopsy, debridement, reconstruction, and stabilization of pyogenic vertebral osteomyelitis. *Global Spine J.* 2014;4:93-100.
12. Mohamed AS, Yoo J, Hart R, et al. Posterior fixation without debridement for vertebral body osteomyelitis and discitis. *Neurosurg Focus.* 2014;37:E6.
13. Jevtic V. Vertebral infection. *Eur Radiol.* 2004;14(suppl 3):E43-E52.
14. Lener S, Hartmann S, Barbagallo GMV, Certo F, Thome C, Tschugg A. Management of spinal infection: a review of the literature. *Acta Neurochir (Wien).* 2018;160:487-496.
15. Fisher CG, DiPaola CP, Ryken TC, et al. A novel classification system for spinal instability in neoplastic disease: an evidence-based approach and expert consensus from the Spine Oncology Study Group. *Spine (Phila Pa 1976).* 2010;35:E1221-E1229.
16. Fox S, Spiess M, Hnenny L, Fourny DR. Spinal Instability Neoplastic Score (SINS): reliability among spine fellows and resident physicians in orthopedic surgery and neurosurgery. *Global Spine J.* 2017;7:744-748.
17. Campos M, Urrutia J, Zamora T, et al. The Spine Instability Neoplastic Score: an independent reliability and reproducibility analysis. *Spine J.* 2014;14:1466-1469.
18. Arana E, Kovacs FM, Royuela A, et al. Spine Instability Neoplastic Score: agreement across different medical and surgical specialties. *Spine J.* 2016;16:591-599.
19. Courjon J, Lemaigen A, Ghout I, et al. Pyogenic vertebral osteomyelitis of the elderly: characteristics and outcomes. *PLoS One.* 2017;12:e0188470.
20. Eren Gok S, Kaptanoglu E, Celikbas A, et al. Vertebral osteomyelitis: clinical features and diagnosis. *Clin Microbiol Infect.* 2014;20:1055-1060.
21. Burke DR, Brant-Zawadzki M. CT of pyogenic spine infection. *Neuroradiology.* 1985;27:131-137.
22. Barton B, Peat J. *Medical Statistics: A Guide to SPSS, Data Analysis and Critical Appraisal.* 2nd ed. Wiley; 2014.
23. Dai LY, Chen WH, Jiang LS. Anterior instrumentation for the treatment of pyogenic vertebral osteomyelitis of thoracic and lumbar spine. *Eur Spine J.* 2008;17:1027-1034.
24. Ruf M, Stoltze D, Merk HR, Ames M, Harms J. Treatment of vertebral osteomyelitis by radical debridement and stabilization using titanium mesh cages. *Spine (Phila Pa 1976).* 2007;32:E275-E280.
25. Sundararaj GD, Babu N, Amritanand R, et al. Treatment of haematogenous pyogenic vertebral osteomyelitis by single-stage anterior debridement, grafting of the defect and posterior instrumentation. *J Bone Joint Surg Br.* 2007;89:1201-1205.
26. Rajasekaran S. Buckling collapse of the spine in childhood spinal tuberculosis. *Clin Orthop Relat Res.* 2007;460:86-92.
27. Park SM, Kim H, Ha JH, et al. The Spinal Instability Neoplastic Score (SINS) as a surgical decision-making tool for the treatment of spine metastasis. *J Korean Soc Spine Surg.* 2018;25:60-68.
28. Duarte RM, Vaccaro AR. Spinal infection: state of the art and management algorithm. *Eur Spine J.* 2013;22:2787-2799.
29. Fourny DR, Frangou EM, Ryken TC, et al. Spinal instability neoplastic score: an analysis of reliability and validity from the spine oncology study group. *J Clin Oncol.* 2011;29:3072-3077.
30. Kim UJ, Bae JY, Kim SE, et al. Comparison of pyogenic post-operative and native vertebral osteomyelitis. *Spine J.* 2019;19:880-887.
31. Taylor DG, Buchholz AL, Sure DR, et al. Presentation and outcomes after medical and surgical treatment versus medical treatment alone of spontaneous infectious spondylodiscitis: a systematic literature review and meta-analysis. *Global Spine J.* 2018;8(4 suppl):49S-58S.